

Nucleus-splitting phacoemulsification technique

S. Gregory Smith, M.D.

ABSTRACT

A technique for phacoemulsification that can be used with or without capsulorhexis and that allows surgery to be performed at the 12 o'clock position is described. Following central sculpting, the nucleus is tipped superiorly to the level of the iris plane with a second instrument and the phacoemulsification tip. The hard nucleus is split from the soft nucleus, leaving two bowl-shaped pieces. The nucleus is rotated and the hard nucleus is removed with a phacoemulsification tip while the softer nucleus or epinucleus is ignored. Once the hard nucleus has been removed, the epinucleus follows easily into the phacoemulsification tip. The technique is advantageous for beginning phacoemulsification surgeons and offers an alternative for very hard nuclei with small pupils.

Key Words: capsulorhexis, epinucleus, hard nucleus, nucleus splitting, phacoemulsification, relaxing tear, soft nucleus

A variety of techniques for performing phacoemulsification have been developed. This paper describes a technique that gives the surgeon good control of the procedure and minimizes trauma to the endothelium and the posterior capsule. The procedure is performed through a small capsulorhexis incision, which makes nucleus prolapse more difficult.

The majority of human lenses appear to have three parts rather than two. In addition to a hard

From Wills Eye Hospital, Philadelphia, Pennsylvania.

Presented in part at the Pennsylvania State University Phacoemulsification Techniques meeting, September 1986.

Reprint requests to S. Gregory Smith, M.D., 1700 Shallcross Avenue, Suite 2, Wilmington, Delaware 19806.

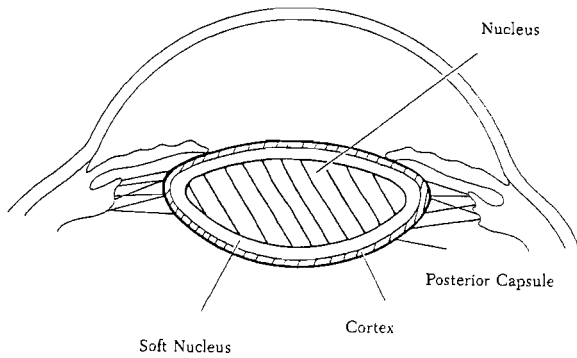


Fig. 1. (Smith) The human lens with its central hard nucleus, a soft nucleus which surrounds the hard nucleus and is a transition layer between the nucleus and the cortex, the cortex, and the posterior capsule.

nucleus and a soft cortex, there seems to be a transition zone, which I call the soft nucleus, that is not quite nucleus or soft cortex (Figure 1). This zone does not aspirate easily with the irrigation/aspiration handpiece. Most surgeons have seen this third nuclear part during extracapsular cataract extraction (ECCE); occasionally there is a residual plate of material following nucleus expression that aspirates very slowly. Koch¹ has recently referred to this as inner hard nucleus.

The basis of the technique described here is using the soft nucleus, which tends to be rigid but is easily aspirated by the phacoemulsification tip, to gain more control during the procedure.

SURGICAL TECHNIQUE

After an anterior capsulotomy, phacoemulsification removes the most anterior layer of the nucleus. A second and third layer are then sculpted (Figures 1, 2, 3). No hydrodissection is done prior to this. Once initial phacoemulsification has been completed, the nucleus is rotated (Figure 4) by applying slow, steady pressure in a clockwise or counterclockwise direction. The nucleus may not dislodge quickly, particularly if there is only moderate nuclear sclerosis. Often the phacoemulsification tip is just held with pressure applied. It may take 10 to 15 seconds for the nucleus to break free from the cortical adherence. This technique is repeated until the nucleus will rotate freely within the capsular bag. It is important to rotate the nucleus rather than simply pressing toward the six o'clock position so pressure on the zonules and possible zonular disruption is avoided.

If the nucleus is soft, rotation with the phacoemulsification handpiece is usually done early in the procedure, often after the first level of sculpting has been performed. If the nucleus is hard, rotation is

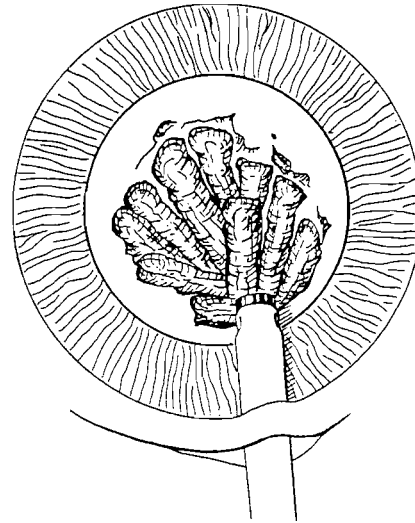


Fig. 2. (Smith) Central sculpting.

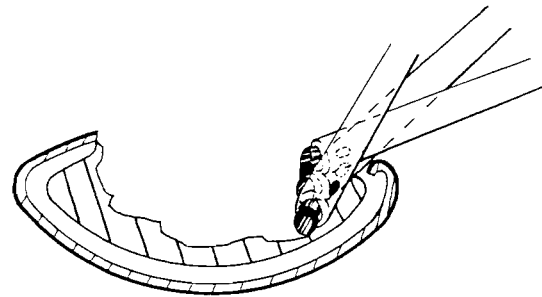


Fig. 3. (Smith) Sagittal view of the phacoemulsification tip position at the start of central sculpting.

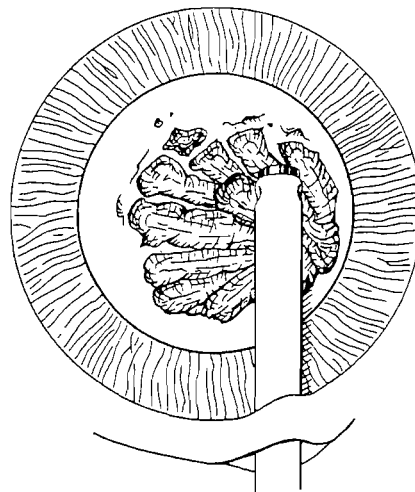


Fig. 4. (Smith) Rotation of the nucleus with a phacoemulsification tip.

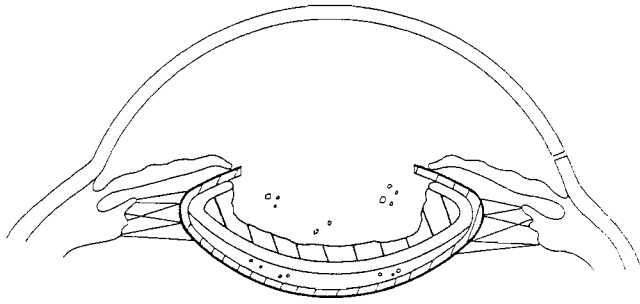


Fig. 5. (Smith) Sagittal view of the hard and soft nucleus when rotation occurs. These two lens portions will separate as a unit from the cortex and allow 0.5 mm or more clearance between the nucleus and the posterior capsule.

done much later. When the nucleus is rotated in this way, it breaks free from the cortex and floats anteriorly, which allows approximately 1 mm of space between the posterior capsule and the phacoemulsification tip if the surgeon should go through the nucleus while trying to thin it out (Figure 5).

Following rotation, the edges of the nucleus are sculpted as much as possible, depending on visibility (Figures 6, 7). The objective is to turn the bowl-shaped nucleus into a plate. When this has been accomplished, the superior pole of the nucleus is prolapsed. A Bechert nucleus manipulator is placed through a separate stab incision at the 2 o'clock position. The phacoemulsification handpiece is placed superiorly, just behind the anterior capsule and iris. The footpedal is in position zero. As the superior pole prolapses superiorly, the phaco handpiece is slid underneath it and the footpedal is placed back into position one to reform the chamber. If the edges have been well sculpted, the nucleus will float up easily. There will be no adherence to the cortex since the nucleus has been rotated, and the capsule will not hold the nucleus down since the nucleus is thin peripherally. If the nucleus does not come easily, more sculpting of the edges is necessary to prolapse the superior pole.

Once the superior pole has been prolapsed, the nucleus is split by placing the Bechert nucleus manipulator underneath the hard nucleus and lifting it anteriorly (Figures 8, 9). The phacoemulsification tip is brought from below the nucleus to the same point as the nucleus manipulator. It is introduced into the nucleus and used to press on the soft nucleus to separate it from the hard nucleus. The nucleus is rotated slightly and the plane of separation extended. Phacoemulsification of the hard nucleus is then performed going over the soft nucleus. The Bechert nucleus manipulator is used to rotate and apply upward pressure on the hard nucleus during phacoemulsification. The remaining soft nucleus is

then aspirated with low pulses of power (Figures 10, 11), having maintained the position of the posterior capsule while the hard nucleus was removed. The soft nucleus has excellent followability and once engaged is easily removed.

RESULTS

Of 494 consecutive cataract extractions performed, three were performed using ECCE and the remainder were done with phacoemulsification using this basic technique. Posterior capsular tears occurred in eight cases; four were due to capsulorhexis extensions. In these cases the capsulorhexis tear extended to the equator despite attempts to redirect or reconnect it by tearing the capsule from the opposite direction or using a can-opener capsulotomy for the remainder. Following phacoemulsification, this tear was extended to the anterior capsule and into the posterior capsule. There was no vitreous loss associated with these tears or loss of nuclear contents. In

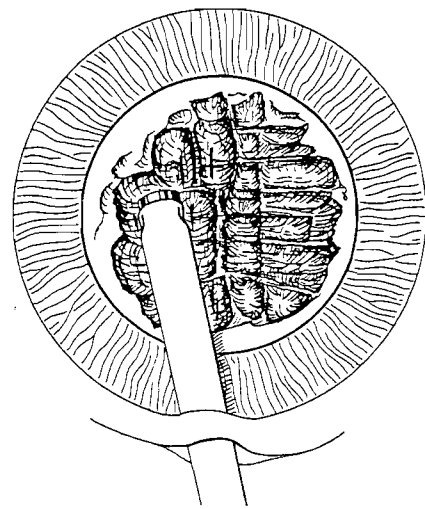


Fig. 6. (Smith) Further sculpting to thin the nucleus and remove the edges of the bowl-shaped hard and soft nucleus.

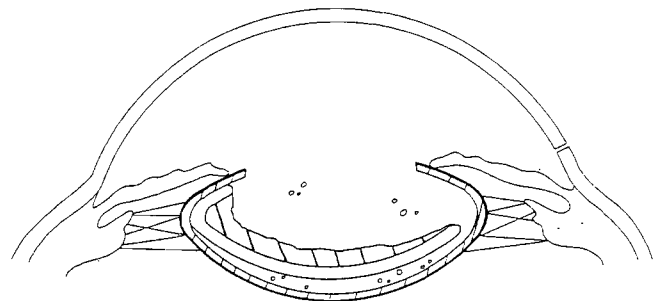


Fig. 7. (Smith) Sagittal view after one edge of the nucleus has been removed.

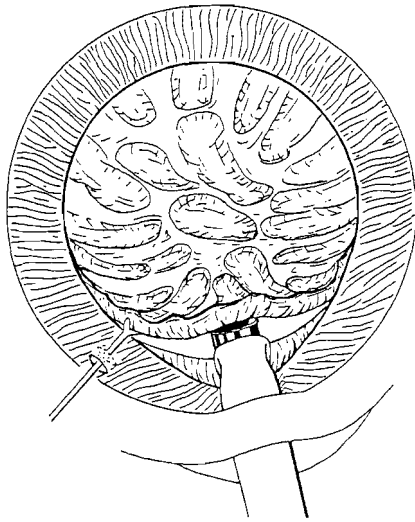


Fig. 8. (Smith) Prolapsing the superior pole of the nucleus, then splitting the hard nucleus from the soft nucleus.

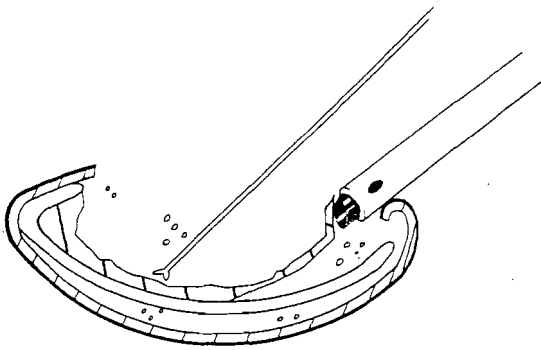


Fig. 9. (Smith) Splitting the hard nucleus from the soft nucleus.

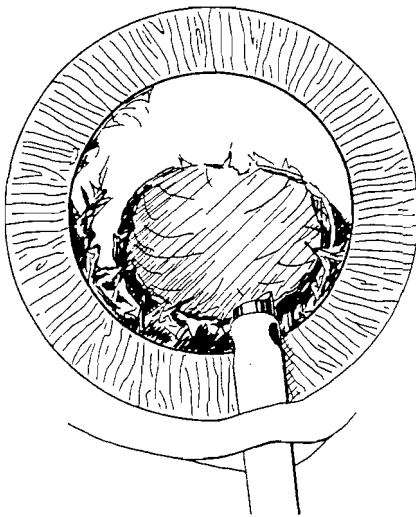


Fig. 10. (Smith) Surgeon's view of aspiration of the soft nucleus.

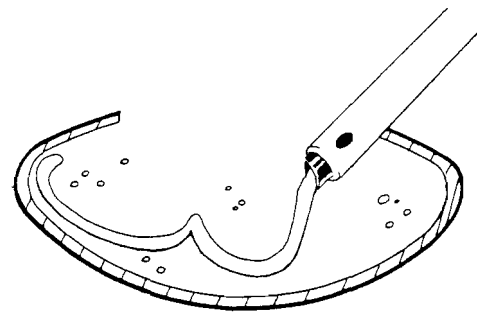


Fig. 11. (Smith) Sagittal view of aspiration of the soft nucleus.

one patient a tear in the posterior capsule developed during posterior chamber lens insertion. This required vitrectomy. In another patient the posterior capsule ruptured because of an untoward reaction associated with the anesthesia and the patient sitting up during the procedure. This occurred during irrigation/aspiration and required vitrectomy. In two other patients tears in the posterior capsule developed during irrigation/aspiration but did not require vitrectomy.

DISCUSSION

The phacoemulsification technique described in this report has given me excellent control of the eye at all points during the phacoemulsification procedure and has reduced the risk to the posterior capsule that often occurs near the completion of the procedure.

The anterior capsulotomy technique for these cases was a capsulorhexis. In the majority of cases, the capsulorhexis was performed by using a straight 25-gauge needle to incise the anterior capsule at the 12 o'clock position. The flap was directed with either a bent cystotome or a Utrata capsule forceps to form a round capsulotomy. In some cases this caused a weakness in the capsule at the 12 o'clock position, particularly if the nucleus was hard. A tear at the 12 o'clock position resulted; however, none of these tears extended to the posterior capsule. More recently, the capsulorhexis has been modified to begin in the center of the capsule so the tear is continuous and all the edges are made by tearing rather than incising. A more durable, round anterior capsulotomy results; however, if the capsulotomy is small, it is more difficult to perform this type of phacoemulsification. If a very hard nucleus is to be emulsified, the capsulorhexis should be made with the straight cystotome starting the tear at the 12 o'clock position so the capsule can relax there and the technique can be performed more easily.

Whether the capsulorhexis is perfect or has a relaxing tear at the 12 o'clock position has made minimal difference clinically. When three-piece lenses were used, only one patient had a significant decentration. With a rigid one-piece lens no decentrations have occurred even in one case with a very small capsulorhexis in which the anterior capsule occluded the pupillary space as it fibrosed. A YAG anterior capsulotomy was performed on this patient and the visual acuity improved from 20/50 to 20/40.

For the surgeon in transition from ECCE to phacoemulsification, starting the capsulorhexis with stab incisions in the anterior capsule at 12 o'clock will facilitate the surgical procedure and result in minimal lens complications even though the anterior capsulotomy is not continuous at 12 o'clock. For an experienced surgeon, this technique with an initial weak area in the anterior capsule at 12 o'clock may be helpful for very hard nuclei.

REFERENCE

1. Koch PS. The "spring" one-stitch phaco technique. MVP Video Journal of Ophthalmology 1990; 6(3)