

Surgical outcome of phacoemulsification combined with the Pearce trabeculectomy in patients with glaucoma

Louis R. Pasquale, M.D., S. Gregory Smith, M.D.

ABSTRACT

The safety and efficacy of phacoemulsification and posterior chamber lens insertion combined with the Pearce trabeculectomy (PE/PCL/P-TRX) in patients with coexistent cataract and glaucoma was evaluated retrospectively. The Pearce trabeculectomy is a form of nonfiltration glaucoma surgery in which an inner block containing trabecular meshwork is excised under a scleral-pocket incision which is closed tightly. Thirty consecutive eyes sustained a reduction of mean intraocular pressure from 21.0 ± 4.4 mm Hg to 16.6 ± 3.3 mm Hg after PE/PCL/P-TRX at one year ($P < .001$). The average number of glaucoma medications used was reduced from 1.9 to 0.8 postoperatively. At one year, 60% (18 of 30) of eyes treated with PE/PCL/P-TRX had intraocular pressures less than 21 mm Hg without medications.

Key Words: cataract, filtering bleb, glaucoma, intraocular pressure, scleral filtration, trabeculectomy

The management of patients with coexistent cataract and glaucoma is constantly evolving as the cataract extraction technique changes. Previously published series indicate that acceptable intraocular pressure (IOP) control and visual outcomes can be achieved after extracapsular cataract extraction (ECCE) and trabeculectomy in eyes with cataract and glaucoma.¹⁻⁴ However, Simmons et al.² observed that only 12% (9 of 75) of their patients had filtration blebs after 12 months. In fact, Murchison and Shields⁵ noted a bleb duration of less than seven weeks for combined procedures regardless of whether a limbal-based or fornix-based flap was used. These observations challenge the notion that subconjunctival filtration plays a critical role in long-term IOP control for these patients. The complications of filtration surgery such as choroidal effusions, flat anterior chamber, late endophthalmitis, and hypotony outweigh the benefits in eyes with a visually significant cataract and

well-controlled glaucoma. However, IOP control in glaucoma patients treated with ECCE and posterior chamber lens insertion alone is often poor and can lead to worsening of the visual field.^{6,7} In addition, if uncontrolled IOP develops after cataract extraction, filtration surgery is less likely to succeed.

A form of glaucoma surgery that achieves modest IOP control while avoiding the complications attendant to filtration surgery seems appropriate for selected patients with cataract and glaucoma. Pearce has proposed a form of nonfiltration glaucoma surgery (personal communication, June 1986), that is a modification of the technique originally described by Cairns.⁸ The Pearce trabeculectomy (P-TRX) differs from standard glaucoma filtration surgery in that a 1 mm \times 4 mm piece of trabecular meshwork is excised and the wound is closed watertight. No attempt to achieve subconjunctival filtration is made.

From the Wilmer Ophthalmological Institute, Baltimore, Maryland (Pasquale), and Wills Eye Hospital, Philadelphia, Pennsylvania (Smith).

Presented in part at the Symposium on Cataract, IOL and Refractive Surgery, Los Angeles, March 1990.

Gaye Webb reviewed charts; Drs. Yoseph Glovinsky, Robert Derick, Henry Jampel, and Harry Quigley reviewed the paper.

Reprint requests to S. Gregory Smith, M.D., 1700 Shallcross Avenue, Wilmington, Delaware 19806.

This study examined the safety and efficacy of phacoemulsification and posterior chamber lens insertion combined with the Pearce trabeculectomy (PE/PCL/P-TRX) in patients with visually significant cataracts and glaucoma.

MATERIALS AND METHODS

We performed a retrospective analysis of 35 consecutive eyes having PE/PCL/P-TRX with a fornix-based conjunctival flap. Five eyes were lost to follow-up prior to one year and were excluded from this review. All surgery was performed between July 1986 and August 1989 by one surgeon (S.G.S.). For each patient, preoperative IOP was defined as the mean of three determinations obtained prior to surgery. Postoperative IOPs were noted at one day, one week, one month, and one year. All patients had visual field defects consistent with glaucoma or ophthalmoscopic evidence of glaucomatous optic neuropathy associated with untreated IOP above 21 mm Hg and a visually significant cataract. All cup-to-disc (C/D) ratio de-

terminations were made using slitlamp biomicroscopic evaluation of the optic nerve.

After obtaining informed consent, all surgery was performed under local anesthesia with standby intravenous sedation in the following manner: After creating a fornix-based conjunctival flap, a half-depth scleral incision with 7 mm chord length was fashioned 1 mm posterior to the limbus. An incision into the anterior chamber was made to accommodate the phacoemulsification handpiece (Figure 1). The nucleus was emulsified and the residual cortex was aspirated. The wound was extended to 7 mm to insert a poly(methyl methacrylate) posterior chamber lens. After gently depressing the corneal lip, the posterior lip of the wound was grasped with toothed forceps (Figure 2) and a 1 mm × 4 mm to 1 mm × 5 mm strip of trabeculum was excised with Vannas scissors (Figures 3 and 4). Subsequently the viscoelastic agent was removed, but iridectomies and intracameral injection of miotics were not performed unless significant chafing of the superior iris occurred during phacoemulsification. Watertight closure of the sclera was obtained

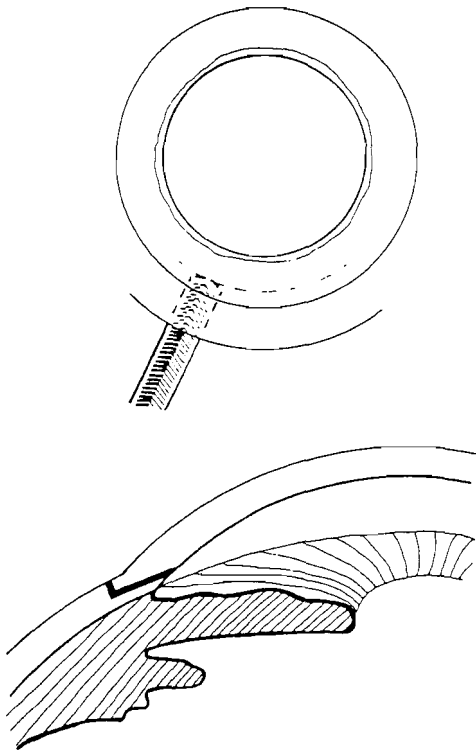


Fig. 1. (Pasquale) A partial-thickness scleral flap with a 7 mm chord length is made 1 mm posterior to the limbus and phacoemulsification is performed.

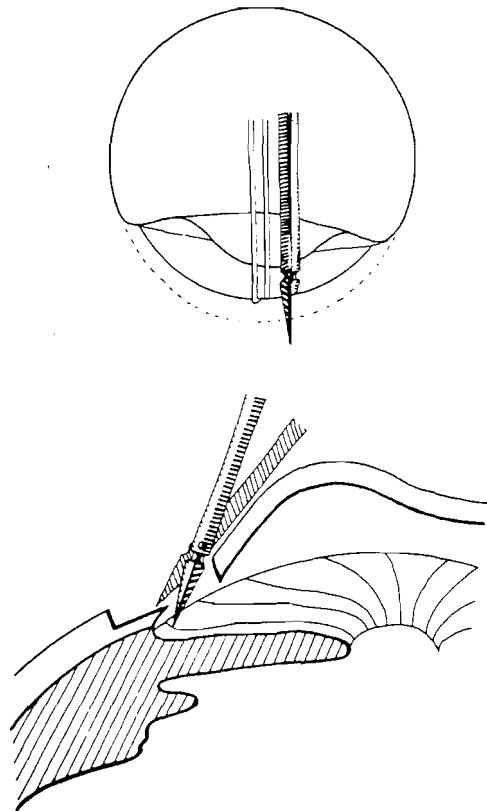


Fig. 2. (Pasquale) After intraocular lens insertion, the posterior lip of the wound is grasped with forceps and Vannas scissors are used to begin removing an inner block.

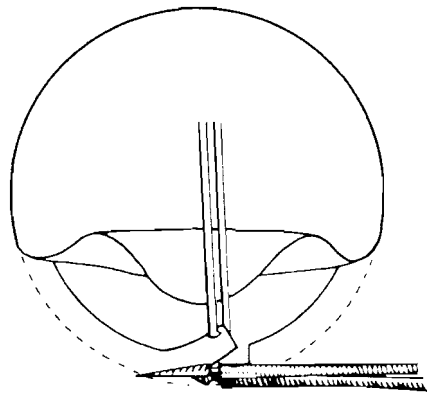


Fig. 3. (Pasquale) The cornea is gently retracted and a 1 mm × 4 mm or 1 mm × 5 mm strip of trabecular meshwork is excised using Vannas scissors.

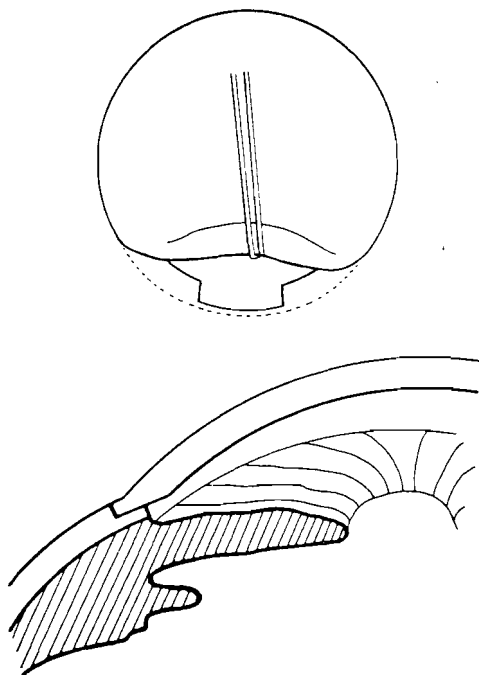


Fig. 4. (Pasquale) The cornea is retracted with forceps to illustrate the appearance of the surgical wound after complete removal of the inner block. At this point the surgical wound is closed tightly.

with a running suture of 10-0 nylon. The conjunctiva was sutured at the limbus with 6-0 plain gut.

Statistical analysis was performed with the Student's *t*-test.

RESULTS

The mean age for patients in this study was 72 years (range 56 to 89 years). Eleven percent of patients were black. Three patients had bilateral

Table 1. Preoperative glaucoma diagnoses.

Diagnosis	Number of Eyes
Open-angle glaucoma	25
Primary	23
Exfoliation	1
Low tension	1
Narrow-angle glaucoma	4
Chronic (primary)	2
Mixed mechanism	2
Unspecified	1

surgery and both eyes were entered into this analysis. Preoperative glaucoma diagnoses are listed in Table 1. Twenty-five of 30 eyes had a form of open-angle glaucoma; four had a form of narrow-angle glaucoma. For 10 of 30 eyes, preoperative IOP was between 18 mm Hg and 31 mm Hg on maximal tolerated medical therapy associated with a C/D ratio greater than or equal to 0.8. The remaining eyes had less severe glaucoma. Overall, the mean C/D ratio for eyes in this study was 0.7.

Intraoperatively, 12 of 30 eyes required a temporary sector iridectomy so phacoemulsification could be performed safely. Posterior capsular rupture or vitreous loss was not encountered.

On the first postoperative day the mean IOP was reduced from 21.0 ± 4.4 mm Hg preoperatively to 12.4 ± 8.1 mm Hg (Table 2). While 9 of 30 eyes had an IOP less than 8 mm Hg, 4 eyes had an IOP in the 20s and one eye had an IOP of 42 mm Hg. During the first postoperative month only one eye exhibited an IOP spike 15 mm Hg above baseline. In this same period, only three eyes experienced significant IOP spikes of 12 mm Hg (two) and 6 mm Hg (one) above baseline, accounting for the wide range of IOP at one day and one week postoperatively (Table 2).

At one year there was a statistically significant 4.4 mm Hg drop in mean IOP ($P < .001$). The mean

Table 2. Effect of the Pearce trabeculectomy on IOP.

Measurement	Average IOP ± S.D. (mm Hg)	Range (mm Hg)
Preoperative	21.0 ± 4.4	13–31
Postoperative		
1 day	12.4 ± 8.1	4–42
1 week	16.1 ± 7.1	5–37
1 month	16.1 ± 4.2	9–25
1 year	16.6 ± 3.3	12–24

number of glaucoma medications required was reduced from 1.9 to 0.8 postoperatively. Only one eye required an increase in the number of medications used after surgery. No patient required additional glaucoma surgery after PE/PCL/P-TRX. Overall, 60% of eyes (18 of 30) required no medications to maintain an IOP less than 21 mm Hg after surgery. All patients required glaucoma therapy preoperatively. The mean IOP for patients who did not require medications postoperatively was 14 mm Hg.

At one year, 62% of patients regained a visual acuity of 20/40 or better. When the eyes with pre-existing conditions that limited visual potential were excluded (Table 3), 83% of eyes treated with PE/PCL/P-TRX achieved a visual acuity of 20/40 or better.

One patient developed cystoid macular edema after surgery that eventually resolved. The three eyes that developed IOP spikes were successfully managed with medical therapy. Complications such as flat anterior chamber and choroidal effusions were not seen after PE/PCL/P-TRX. Four eyes developed transient hyphemas that resolved and were not clinically significant. No filtering blebs were noted in short- or long-term follow-up. The two eyes with pre-existing corneal disease required penetrating keratoplasty postoperatively. This was not a complication of phacoemulsification. For these eyes follow-up IOPs were included from the post-keratoplasty period.

DISCUSSION

This is the first reported series of phacoemulsification combined with a form of nonfiltration glaucoma surgery in patients with coexistent cataract and glaucoma. We found a statistically significant IOP reduction when the Pearce trabeculectomy was combined with phacoemulsification. While the IOP reduction achieved was statistically significant, one may argue that it was not clinically important. The last preoperative and postoperative

Table 3. Concurrent preoperative diagnoses potentially limiting visual outcome.

Diagnosis	Number of Eyes
Central glaucomatous visual field defect	4
Age-related macular disease	2
Temporal arteritis, Fuch's corneal dystrophy, keratopathy secondary to acid burn	3 (one each)
Total	9

IOP reading is subject to variable patient compliance and diurnal swings. We tried to reduce this effect by defining the preoperative IOP as the mean of three determinations immediately prior to surgery. Sixty percent of eyes (18 of 30) that had PE/PCL/P-TRX required no medications to maintain an IOP less than 21 mm Hg after surgery, supporting a therapeutic role for the P-TRX. In addition, short-term IOP control after PE/PCL/P-TRX compared favorably to short-term IOP control after cataract extraction alone in glaucoma patients. For instance, Savage and coauthors⁷ noted that in 31 of 139 (22%) glaucomatous eyes having ECCE/PCL alone, an IOP spike 15 mm Hg above baseline was recorded in the first eight weeks after surgery. We found a similar pressure elevation in only one of 30 eyes (3%) undergoing PE/PCL/P-TRX in the first month after surgery. McGuigan et al.⁶ found 23 of 37 glaucomatous eyes (62%) with an IOP at least 7 mm Hg above baseline on the day after cataract surgery. We found only 3 of 30 eyes (10%) with a spike of this magnitude in the first postoperative month.

This study does not address the issue of whether phacoemulsification alone affects long-term IOP control in glaucoma patients. However, the literature indicates that carefully performed ECCE/PCL has little effect. Radius et al.⁹ noted a 0.6 mm Hg reduction in IOP in a large series of patients without a history of glaucoma after ECCE/PCL (N = 209 eyes, P = .05). Handa and coauthors¹⁰ evaluated a group of patients with glaucoma who had ECCE/PCL. They found a small long-term reduction in pressure postoperatively (1.4 mm Hg) and the mean number of glaucoma medications used was not substantially reduced. There is no reason to believe that these results would be altered by phacoemulsification alone.

None of our patients had clinically apparent

Table 4. Surgical outcome of combined procedures for various investigators.

Investigator	Visual Acuity ≤ 20/40	IOP < 21 mm Hg Off Medications
	Number (Percent)	Number (Percent)
Pfoff	18 (95)	7 (37)
Ohanesian and Kim	24 (67)	20 (55)
Simmons et al.	49 (65)	38 (50)
McCartney et al.	84 (78)	62 (57)
Pasquale and Smith	19 (62)	18 (60)

Table 5. Surgical outcome of combined procedures for various investigators.

Investigator	Mean IOP (mm Hg)		Mean Number of Medications Used	
	Preoperative	Postoperative	Preoperative	Postoperative
Pfaff	19.0	15.7	2.5	0.8
Ohanesian and Kim	27.0	18.0	2.7	0.7
Simmons et al.	19.3	16.3	2.3	0.8
McCartney et al.	23.3	17.1	1.6	0.5
Pasquale and Smith	21.0	16.6	1.9	0.8

blebs; nevertheless, filtration through the wound may affect pressure control in the immediate postoperative period. Flow through the cut ends of Schlemm's canal, as originally proposed by Cairns, may also contribute to early IOP control; however, as wound healing proceeds, the cut ends of Schlemm's canal close.¹¹ The mechanism of how the P-TRX affects long-term IOP control is entirely unclear.

We compared our results with PE/PCL/P-TRX to reports of ECCE/PCL combined with standard trabeculectomy (Tables 4 and 5). Studies with small numbers of eyes (less than ten), inadequate follow-up (less than six months), or studies that included patients with ocular hypertension were excluded. The mean preoperative IOP in the series shown in Table 5 ranged from 19.0 mm Hg to 27.0 mm Hg. The postoperative IOP and average number of medications used were quite similar. Our postoperative results compare favorably with these previously published series. While McCartney and coauthors¹ and Ohanesian and Kim³ achieved larger IOP reductions, their patients had higher preoperative IOPs. A significant number of their patients required chronic ocular massage or laser modification of the sclerostomy site to maintain a reduced IOP. Our results on combined procedures were most similar to Simmons et al.² who noted only 9 of 75 eyes had filtration blebs after 12 months. Our visual outcomes and overall IOP control compared favorably with those of previous investigators (Table 5).

Based on these results, we feel further investigation of the P-TRX is indicated. A prospective, randomized study comparing PE/PCL/P-TRX to phacoemulsification and posterior chamber lens insertion combined with standard trabeculectomy using subconjunctival filtration would be useful in delineating visual outcome, final refraction, IOP control, and complication rate for each group. The

advantage of combining the P-TRX with cataract extraction is that short-term IOP control is attained without the attendant complications associated with filtration surgery. The disadvantage is that one can not resort to massage or laser suture lysis for cases in which IOP is elevated.

REFERENCES

1. McCartney DL, Memmen JE, Stark WJ, et al. The efficacy and safety of combined trabeculectomy, cataract extraction, and intraocular lens implantation. *Ophthalmology* 1988; 95:754-763
2. Simmons ST, Litoff D, Nichols DA, et al. Extracapsular cataract extraction and posterior chamber intraocular lens implantation combined with trabeculectomy in patients with glaucoma. *Am J Ophthalmol* 1987; 104:465-470
3. Ohanesian RV, Kim EW. A prospective study of combined extracapsular cataract extraction, posterior chamber lens implantation, and trabeculectomy. *Am Intra-Ocular Implant Soc J* 1985; 11:142-145
4. Pfaff DS. Simultaneous extracapsular cataract extraction, intraocular lens implantation, and posterior lip sclerectomy filtering procedure in glaucoma patients. *CLAO J* 1984; 10:143-147
5. Murchison JF Jr, Shields MB. Limbal-based vs fornix-based conjunctival flaps in combined extracapsular cataract surgery and glaucoma filtering procedure. *Am J Ophthalmol* 1990; 109:709-715
6. McGuigan LJB, Gottsch J, Stark WJ, et al. Extracapsular cataract extraction and posterior chamber lens implantation in eyes with preexisting glaucoma. *Arch Ophthalmol* 1986; 104:1301-1308
7. Savage JA, Thomas JV, Belcher CD III, Simmons RJ. Extracapsular cataract extraction and posterior chamber intraocular lens implantation in glaucomatous eyes. *Ophthalmology* 1985; 92:1506-1516
8. Cairns JE. Trabeculectomy: Preliminary report of a new method. *Am J Ophthalmol* 1968; 66:673-679
9. Radius RL, Schultz K, Sobocinski K, et al. Pseudophakia and intraocular pressure. *Am J Ophthalmol* 1984; 97:738-742
10. Handa J, Henry JC, Krupin T, Keates E. Extracapsular cataract extraction with posterior chamber lens implantation in patients with glaucoma. *Arch Ophthalmol* 1987; 105:765-769
11. Taylor HR. A histologic survey of trabeculectomy. *Am J Ophthalmol* 1976; 82:733